



CO₂ laser treatment as an effective and safe means of achieving genital wart excision

Dr. Acky Friedman, (M.D, L.L.B)

INTRODUCTION

Condyloma acuminata, or genital warts, are small growths that develop externally on the genitalia, in the anal area internally in the upper vagina or cervix, and/or in the male urethra. This highly contagious, sexually transmitted condition, caused by the human papillomavirus (HPV) (Arima et al. 2010), has an incubation period of 3 weeks to 8 months (Yanofsky et al. 2012). Women with genital warts are at an increased risk for cervical cancer, underscoring the importance of careful diagnosis and selection of the appropriate treatment. Genital wart therapies include topical preparations that destroy wart tissue, surgical methods that remove wart tissue, and biological approaches that target the virus underlying the condition. Chemical and topical agents can have a caustic or destructive effect on the surrounding healthy tissue and their repetitive use is contraindicated. In addition, some topical preparations cause a burning sensation, pain, inflammation, itching, or erosion of the affected area. Surgical excision of the warts is accompanied by significant patient pain and scarring and is contraindicated for large anal and perianal lesions. Anti-viral therapies are costly and seldom limit recurrence of the condition (Perisic et al, 2004). Overall, cure rates of traditional treatment modalities are low, with incidence of recurrence within 3-12 months of treatment as high as 70% (Jablonska 1998, Yanofsky et al. 2012). Their unsatisfactory efficacy is primarily rooted in their focus on superficial removal of the wart, while the virus remains in a latent state in the epithelial layer.

CO₂ laser therapies have been often proven to be efficient and safe with low rates of persistence and recurrence (Ferenczy, 1983; Perisic et al, 2004; Azizjalali et al, 2012). Indeed, Bakardzhiev and his colleagues (2012) that treated patients with wide distribution of condylomatous lesions reported on successful eradication accomplished in most of them within one single treatment of CO₂ laser. Lastly, CO₂ laser vaporization was found associated with lower

recurrence rates especially in case of extensive warts and tremendously effective for patients who have not responded to other treatments (Shi H et al ,2013).

CASE

The Technology

The Alma CO₂ laser with its scanner, LiteScan, provide high-precision and char-free tissue ablation, with well controlled layer by layer vaporization enabling minimal damage to the surrounding tissue (Figure 1)



Figure 1. LiteScan Scanner

GENITAL WARTS AROUND THE ANUS: A CASE REPORT

A male, 28 YO patient, presented with small genital warts around the anus (Figure 2).

Local Anesthesia: lidocaine subcutaneous The affected area was sterilized with 70% alcohol.

Settings: The Alma CO₂ Pixel Laser, with a power of 10 W, dwell time of 2.0 msec, 20mj/pixel.

Radiation was usually delivered via the 50mm handpiece for efficient excision.

Prophylaxis: Antibiotic cream twice daily for 7 days

Follow Up: 1 month

Figure 3 shows the area immediately after treatment. The patient did not complain of any discomfort or experience

any bruising. No side effects were observed and the damage to the surrounding tissue was minimal. The patient got back to the clinic after one month to treat genital warts that grew in a different location in the genital area.

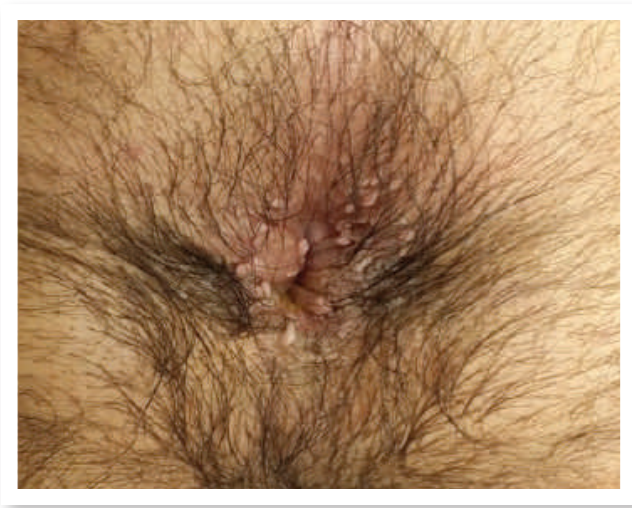

Figure 2. Genital warts scattered around the anus

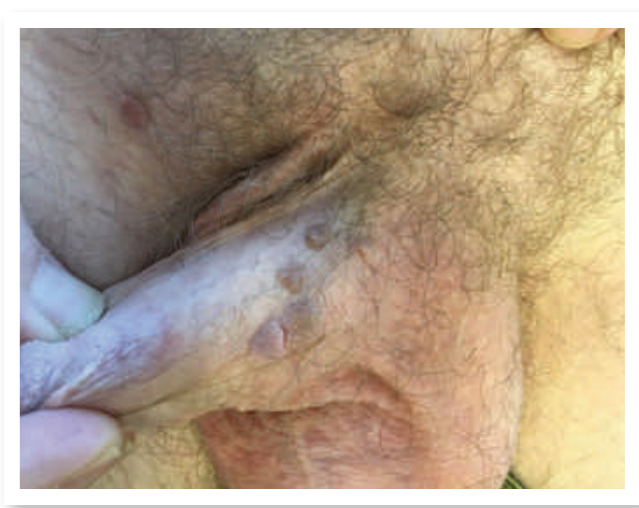


Figure 4. Condyloma scattered around the penis shaft

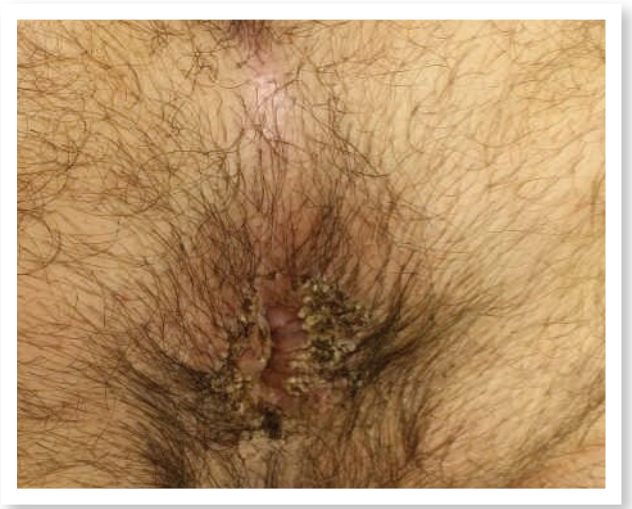

Figure 3. Genital warts immediately after CO2 laser treatment

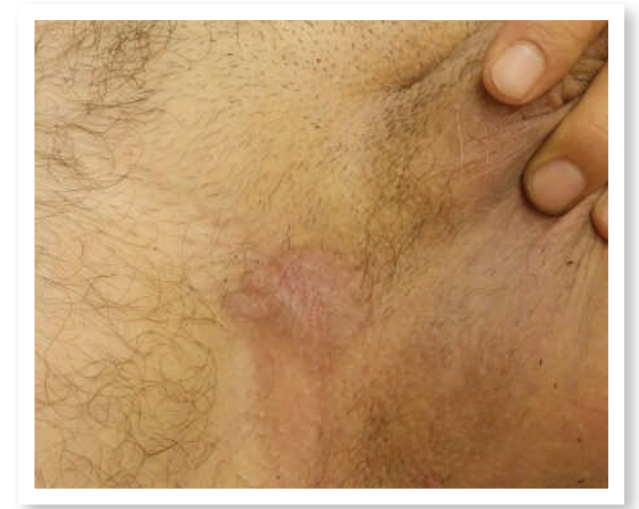

Figure 5. Condyloma 1 month following laser treatment. Almost cured.

ANOTHER TWO CASES

Figure 4 shows a male presenting large genital warts on the shaft of the penis. This male was treated only once with the laser. The genital warts have disappeared within 2 months from treatment.

Another case of a male treated with the laser displayed in Figure 5. This male came to the clinic with a few genital warts in the groin. He was treated only once with a laser.

CONCLUSION

Surveillance follow up calls revealed that many of the patients didn't come back for follow up since the treatment was highly effective without recurrence. Carbon dioxide laser vaporization is a safe, cost-effective and time-effective means of addressing the clinical manifestation and underlying cause of genital warts.

"Alma CO₂ laser is easy to operate in outpatient clinics. The ablative laser, when carefully directed to the field of treatment effectively excises condyloma, reducing its recurrence rate."

*Dr. Acky Friedman, (M.D, L.L.B)
Aesthetics and Dermatology Specialist*

REFERENCES

- Alex Ferenczy (1983) Using the laser to treat vulvar condylomata acuminata and intraepidermal neoplasia. Can Med Assoc J volume 128; p135.
 - Arima Y, Winer RL, Feng Q, et al. (2010) Development of genital warts after incident detection of human papillomavirus infection in young men. J Infect Dis 202:1181-1184.
 - Azizjalali M et al (2012) CO₂ Laser therapy versus cryotherapy in treatment of genital warts; a Randomized Controlled Trial (RCT) Iran J Microbiology 4 (4) : 187-90.
 - Bakardzhiev et al (2012) Treatment of Condyloma Acuminata and Bowenoid papulosis with CO₂ laser and imiquimod. Journal of IMAB Annual Proceeding (Scientific Papers) 2012, vol. 18, book 1
 - Jablonska S (1998) Traditional therapies for the treatment of condylomata acuminata (genital warts) The Australian Journal of Dermatology 39:52-4.
 - Perisic et al (2004) Treatment of condylomata acuminata – surgical excision and CO₂ laser vaporization. Acta Dermatoven APA Vol 13 (1), p9
 - Shi H et al (2013) Dermatology 227(4):338-45
 - Yanofsky VR, Patel RV, Goldenberg G. (2012) Genital warts A comprehensive review J Clin Aesthet Dermatol 5(6):25-36.
-

KEY WORDS

Condyloma, Genital warts, excision, CO₂ laser