

# Non Invasive Labia Majora Tightening & Skin Rejuvenation with CO<sub>2</sub> Laser FemiTight

**Alexander Bader<sup>1</sup>, MD**

## INTRODUCTION

Labia majora are the two prominent longitudinal cutaneous folds located on the outer part of the female genital area, and which extend downward from the mons pubis area to the perineum. Each labium majus has two surfaces, an outer, pigmented surface covered with hair, and an inner, smooth surface, beset with large sebaceous follicles.

As with any other human tissue, the natural course of the labia majora often involves tissue atrophy, which is mainly a consequence of normal vaginal ageing and associated poor circulation and loss of hormonal support, or of pregnancy, delivery and significant weight loss in younger women.

Atrophy of the tissues in this area manifests by loss of labia volume, flaccidity and ptosis. Protuberant labia majora can lead to functional difficulties in sexual stimulation and satisfaction, complicate hygiene maintenance, influence choice of undergarments and swimsuits and negatively impact self-confidence and self-image. These aesthetic, psychological and/or functional effects often drive women to seek labiaplasty solutions.

Labia Majora Plasty can be approached via radical and invasive procedures, in which part of the labia majora skin is surgically removed, while the remaining tissue is lifted and stretched. Yet, these techniques are associated with clinical sequelae, such as nerve ending damage, significant anatomical deformities, scarring and hair growth toward the vaginal entrance, which can further exacerbate patient discomfort and dissatisfaction.

An innovative, noninvasive, nonablative, CO<sub>2</sub> fractional laser-based therapy has an established dermal rejuvenation effect, stimulated by gentle heating of a region of interest and subsequent selective induction of collagen generation and deposition in the deep tissue layers. The resulting improvement in skin texture and wrinkle scores closely correlates with high patient and physician satisfaction. This case report describes its application toward labia majora remodeling.

## CASE

A 39-year-old woman complained of 5 years of psychological and aesthetic dissatisfaction with the appearance of her labia majora. She reported low self-confidence, and embarrassment during gym and swimming activities, as well as during intercourse.

She had been practicing a waxing method for hair removal for the last 10 years and had recently begun photoepilative treatment in the vaginal area. The patient had a record of three vaginal deliveries, with no serious medical issues and no record of any kind of invasive procedures in this specific area.

On examination, the labia majora lacked normal shape and presented long and deep wrinkles along their surface. The skin showed excessive laxity with poor elasticity. The treatment plan was introduced to the patient as a means of eliciting cosmetic rejuvenation, with no claims to enhance sexual function or gratification.

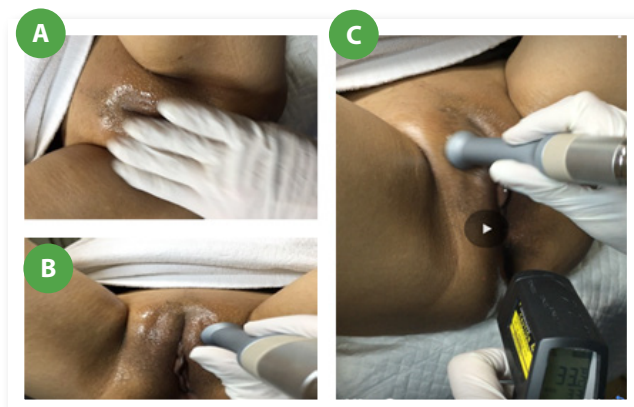
<sup>1</sup> Director of HB Health Reconstructive & Cosmetic Gynecology department, London, United Kingdom

## METHOD

A local anesthetic (lidocaine 2% mixed with N/S 0.9% (1:1)) was injected using a 27 G needle. The area was cleaned with an iodine-free antiseptic solution and thoroughly dried. A thin layer of oil was then applied over the entire area to be treated (**Figure 1A**). The FemiLift-T FemiTight “de focus” probe (**Figure 2**), dedicated for labia majora rejuvenation, was then connected to the laser unit and the power was set on the “Repeat mode” at a fluency of 0.5 sec on time (in-motion) and 0.5 sec off time (in-motion).

While continuously pressing the foot pedal, circular movements were made with the hand piece, which was kept in direct contact with the skin throughout (**Figure 1B**). The laser temperature detector was closely monitored to ensure that the duration of the highest allowed temperature (42°C) did not exceed 5 sec (**Figure 1C**).

This temperature, for a duration shorter than 5 sec at the same spot, is considered safe for the human tissue. Usually, human tissue is tolerant of temperatures up to 44°C and, very rarely, 46°C. Beyond these levels, serious tissue insult and irreversible reduction in cell viability occur. Rehydration cream was applied immediately after the treatment and the patient was instructed to continue applying cream for 5 days and recommended to perform an assessment for the need for maintenance treatment after 6 months.



**Figure 1.** CO<sub>2</sub> laser-based labia majora remodeling treatment. **(A)** A thin layer of oil was applied over dry skin. **(B)** The probe was kept in close contact with the skin throughout the procedure and moved in circular motions, while avoid stacking. **(C)** Skin temperature was closely monitored to avoid overheating (>42 °C).

## RESULTS AND CONCLUSIONS

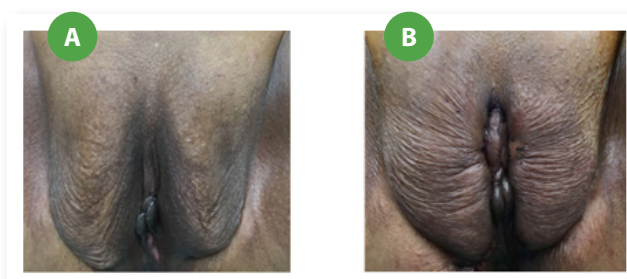
A single-session deployment of CO<sub>2</sub> laser energy significantly enhanced labia majora tissue appearance, as manifested by a distinct lifting effect and improved texture and wrinkle profiles (**Figure 3**).

The procedure was performed in clinic, required a local anesthetic and was completed within 3 minutes. No patient discomfort was reported and the procedure did not involve any downtime; the patient returned to everyday activities immediately thereafter. No special treatment of the area was required following the session.

The patient was pleased with the treatment outcome and is expected to benefit from the results for a period of at least 2 years, which is the life-span of high quality collagen. Overall, this minimally invasive approach presents a simple and highly tolerable labia majora lifting modality, with immediate effects on patient comfort, self-image and self-esteem.

We recommend that patients apply rehydration cream for 4-5 days after treatment. No restrictions or other special instructions are indicated. The patient can return to daily activities, including gym and sexual intercourse, one day after treatment. Results may be visible immediately after the session, but improve over the 3 to 6 months following treatment, which is the estimated time for new collagen regeneration. A maintenance treatment session every year is recommended, particularly if the patient is seeking to enhance the results.

**Figure 2.** FemiTight for Labia Majora Tightening



**Figure 3.** Labia majora before (A) and after (B) CO<sub>2</sub> laser-based labia majora remodeling.

## KEYWORDS

Labia majora, relaxation, skin laxity, collagen remodeling, wrinkles removal, Non-Invasive de focused CO<sub>2</sub> Laser

---

## REFERENCES

1. Manual of Obstetrics. (3rd ed.). Elsevier. pp. 1-16
2. Manstein D, Herron GS, Sink RK, Tanner H, Anderson RR. Fractional photothermolysis: a new concept for cutaneous remodeling using microscopic patterns of thermal injury. *Lasers Surg Med* 2004;34:426-38.
3. Hantash BM, Bedi VP, Kapadia B, et al. In vivo histo-logical evaluation of a novel ablative fractional re-surfacing device. *Lasers Surg Med* 2007;39:96-107.
4. Rahman Z, MacFalls H, Jiang K, et al. Fractional deep dermal ablation induces tissue tightening. *Lasers Surg Med* 2009;4:78-86.
5. Orringer JS, Sachs DL, Shao Y, et al. Direct quanti-tative comparison of molecular responses in pho-todamaged human skin to fractionated and fully ablative carbon dioxide laser resurfacing. *Dermatol Surg* 2012;38:1668-77.
6. Fitzpatrick RE. CO<sub>2</sub> laser resurfacing. *Dermatol Clin* 2001;19:443-51.